

LABORATORY OF ELECTROENCEPHALOGRAPHY

A. F. PETERMAN, M. D.  
 850 Mill Street  
 Reno, Nevada 89502  
 (702) 322-4097

RECEIVED  
 AND FILED

LAST NAME GARRIDO, PHILLIP C.		E.E.G. NO. XXX3 1/6/77 77-3	DATE FEB 1 10 06 AM '77
FIRST NAME	AGE 25	ADDRESS OR INSTITUTION CAROL G. FITZGERALD, CLERK	

BY \_\_\_\_\_  
 DEPUTY

HISTORY - FINDINGS - PROVISIONAL DIAGNOSIS:

MEDICATION:

*darvon*

REFERRING PHYSICIAN/AGENCY: Dr. Peterman  
 Federal Public Defender

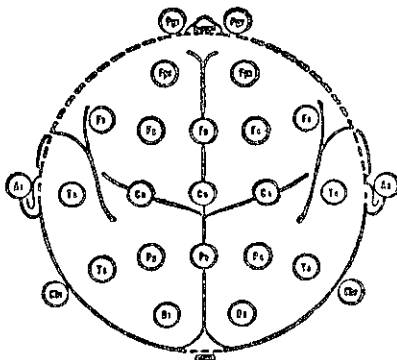
REPORT OF CONSULTATION

DESCRIPTION:

- AWAKE  This tracing contains medium voltage, quite well developed and symmetrical alpha activity in the 9 Hz range posteriorly as well as scattered low voltage beta activity anteriorly but is not otherwise remarkable in the resting state.
- DROWSY
- ASLEEP  Hyperventilation causes no excessive buildup or activation.
- HV.
- PHOTIC

IMPRESSION:

Normal EEG showing no foca, paroxysmal or lateralizing changes.



*[Handwritten Signature]*

A. F. PETERMAN, M. D.

ALBERT F. PETERMAN, M. D., F. A. C. P., CHARTERED  
Neurology

850 Mill Street  
Reno, Nevada 89502  
(702) 322-4097

GARRIDO, PHILLIP C.

JANUARY 6, 1977

25 year old prisoner referred by Dr. Lynn Gerow, Jr.

This man apparently is to be tried for kidnap and rape in Federal Court, has seen Dr. Lynn Gerow, Jr., whose medical consultation I have reviewed, and is evaluated now for the question of any kind of brain damage.

This man has a perfectly bland neurologic history. He was born and raised in Pittsburgh, California, finished the 12th grade of school with B's, C's and occasional D's and after high school had a number of odd jobs and became a musician playing the bass.

He has used a number of drugs in the past primarily LSD, at times quite heavily particularly, as noted by Dr. Gerow, in the early 1970's when he would use "five hits a day".

LSD made him quite sexually aggressive which he realizes.

He had used LSD prior to his alleged offense, but remembers the details of the abduction and sexual activity quite well.

There is no history of significant head injuries, skull fracture or concussion.

There is no history of convulsive disorder of any kind.

He has occasionally and sometimes frequently been out of contact in the past after using drugs of one kind or another, but relates this to drug use.

There is no family history of epilepsy.

This man has had recurrent migraine headaches from a young age pretty well corrected by an allergenic diet, but since being in jail the headaches have recurred.

He also had a cyst on the scalp removed a month or so ago at Washoe Medical Center which has now healed.

He has no specific neurologic complaints per se other than occasional migraine headaches.

An EEG obtained in my office today is entirely normal.

Examination reveals a quite apprehensive, somewhat withdrawn, thin, young man who is alert, well oriented and cooperative.

He did burst into tears on one occasion when I asked him to do some calculations to test organic brain function, but otherwise was reasonably well composed.

ALBERT F. PETERMAN, M. D., F. A. C. P., CHARTERED  
Neurology

850 Mill Street  
Reno, Nevada 89502  
(702) 322-4097

GARRIDO, PHILLIP C.

JANUARY 6, 1977  
(page 2 continued)

He states that he is looking forward to going to court, has found religion and feels his life will change for the better.

He shows appropriate concern for whatever crime he is charged with.

I cannot find any hard evidence of organic brain damage per se.

He can do serial 7's and retain 5 digits in forward and reverse order with considerable concentration.

The cranial nerve function is intact. Pupils and eyegrounds are normal. Visual fields are full to confrontation.

There is no carotid bruit.

Muscle strength and tone and stretch reflexes are unremarkable and symmetrical and there are no pathological reflexes noted.

There is no particular tremor or movement disorder and no gait disturbance, ataxia or Romberg.


Gross and fine sensory testing is unremarkable including traced figures and stereognosis of each hand.

DIAGNOSTIC IMPRESSION:

Normal neurological examination.

I see no evidence either by history, examination or EEG of brain damage per se, although there is considerable evidence of anxiety and depression and personality disorder as noted by Dr. Gerow.

ALBERT F. PETERMAN, M. D.



AFP/kp

cc: Dr. Lynn Gerow, Jr.

cc: Willard Van Hazel, Jr.

Assistant Federal Public Defender